



Clinical study

Necrotizing soft tissue infections developing from pressure ulcers



Fumihiko Mizokami^a, Katsunori Furuta^{a,b}, Zenzo Isogai^{c,*}

^a Department of Pharmacy, National Center for Geriatrics and Gerontology, Japan

^b Department of Clinical Research and Development, National Center for Geriatrics and Gerontology, Japan

^c Division of Dermatology and Connective Tissue Medicine, Department of Advanced Medicine, National Center for Geriatrics and Gerontology, Japan

KEYWORDS

Pressure ulcer;
Soft tissue infection;
Necrotizing fasciitis;
Bacteremia

Abstract *Aim of the study:* Necrotizing soft tissue infections (STIs) are serious complications that may arise from pressure ulcers. However, there are few studies on this important issue. In addition, diagnostic criteria for necrotizing STIs developing from pressure ulcers and infected pressure ulcers are not well established. *Methods:* We defined necrotizing STIs developing from pressure ulcers based on clinical findings. Based on the definition, we retrospectively analyzed the medical records of 24 elderly patients with this condition to determine patient age, gender, comorbid disease, laboratory findings, wound location, bacteriology, and treatment outcomes.

Results: In the examined population, necrotizing STIs developed primarily from pressure ulcers over the sacrum. Dementia and diabetes mellitus were also frequently observed in patients with necrotizing STIs. The average Laboratory Risk Indicator for Necrotizing Fasciitis (LRINEC) score was relatively low. Bacterial cultures from the debrided deep tissues exhibited mixed infections of gram-positive cocci and gram-negative bacilli, except 1 case. Anaerobic pathogens were isolated from 18 patients (72%), and 7 patients (29%) developed bacteremia. None of the cases were preceded by wounds dominated by granulation tissue. Surgical intervention, combined with antibacterial therapy involving intravenous carbapenem or cephem, was successfully used in most cases.

Conclusion: Necrotizing STIs arising from pressure ulcers are generally caused by mixed pathogens and exhibit symptoms that are milder than those of necrotizing fasciitis caused by group A *Streptococcus*.

© 2013 Tissue Viability Society. Published by Elsevier Ltd. All rights reserved.

* Corresponding author. 35 Gengo, Morioka-cho, Obu, Aichi 474-8511, Japan. Tel.: +81 562 46 2311x7156; fax: +81 562 48 2373. E-mail address: zenzo@ncgg.go.jp (Z. Isogai).

Introduction

Necrotic tissue is always present in deep pressure ulcers, and soft tissue infections (STIs) often develop from the necrotic tissue. Some necrotizing STIs, such as necrotizing fasciitis (NF) and gas gangrene are potentially life threatening. NF is characterized by extensive, rapidly progressive necrosis of the fascia, followed by necrosis of the subcutaneous tissue, with an overall mortality rate of 25–30% [1,2]. However, the clinical features of necrotizing STIs developed from pressure ulcers are not well documented [3]. Necrotizing STIs have a significant impact on patients with pressure ulcers because these STIs dramatically increase wound volume and often induce sepsis. Although pressure ulcers develop over bony prominences and infected pressure ulcers have been previously reported [3,4], STIs may also extend beyond the pressure ulcer lesion. Therefore, studies are required to characterize these necrotizing STIs that develop from pressure ulcers.

Generally, NF is the most severe STI and is accompanied by systemic symptoms, including fever and shock. Moreover, NF often leads to sepsis. Therefore, the clinical features of necrotizing STIs are important in the management of pressure ulcers. In addition, whether necrotizing STIs that develop from pressure ulcers show clinical features distinct from fulminant NF (type II NF) is unclear. However, the etiology of necrotizing STIs that develop from pressure ulcers is not well understood. Furthermore, the terminology of “necrotizing STIs from pressure ulcers” and “pressure ulcer infections” has not been defined. This study aimed to investigate the characteristics of necrotizing STIs that develop from pressure ulcers.

Methods

Cases

All patients in this study were observed at a medical center with 300 beds; more than 90% of the patients hospitalized at the medical center were aged >65 years. This retrospective review examined patient medical records created between January 2005 and December 2012. The records of patients who had necrotizing STIs that developed from pressure ulcers were analyzed. This study complied with the ethical tenets for human experimentation outlined in the 1975 Declaration of Helsinki.

The pressure ulcers were staged according to the National Pressure Ulcer Advisory Panel

(NPUAP) criteria, with the wound locations being described according to the bony prominence over which they developed. All patients were analyzed with regard to the recorded surgical interventions, laboratory data, and microbiological and histological findings. The Laboratory Risk Indicator for Necrotizing Fasciitis (LRINEC) score [5] was calculated for each patient on the day of hospital admission using clinical laboratory data comprising white blood cell counts and levels of glucose, C-reactive protein (CRP), sodium, serum creatinine, and hemoglobin. Information about age, gender, anatomical location of the pressure ulcer, antibacterial treatments, and 30-day mortality were extracted from each patient’s medical record.

Definition and diagnosis of necrotizing STIs that develop from pressure ulcers

Necrotizing STIs, including necrotizing fasciitis, gas gangrene, and other clinical entities, cause necrosis of the subcutaneous tissue, fascia, and muscle. However, deep pressure ulcers also result in soft tissue necrosis. To distinguish between the 2 conditions, necrotizing STIs were defined as shown in Fig. 1. Necrotizing STIs were defined as those extending beyond the area immediately over the bony prominence and were, therefore, not limited to the primary ischemic tissue generated by excessive pressure.

In this study, necrotizing STIs that developed from pressure ulcers were diagnosed by a board-certificated dermatologist. In brief, the diagnosis was determined based on the presence of necrotic fascia and fat tissue, accompanied by direct observations during surgical debridement and/or pathological findings and/or computed tomography evidence of the presence of gas within the soft tissue adjacent to the pressure ulcer. Infections limited to necrotic tissue and developing as a result of pressure-induced ischemia were excluded (Fig. 1).

Results

Patient characterization

During the 8-year study period, 624 hospitalized patients were diagnosed with pressure ulcers; 24 (4%) were diagnosed with necrotizing STIs that developed from pressure ulcers (Table 1). Among the 24 patients with STIs, the average age was 82.9 (range, 65–98) years and 14 (58%) were female.

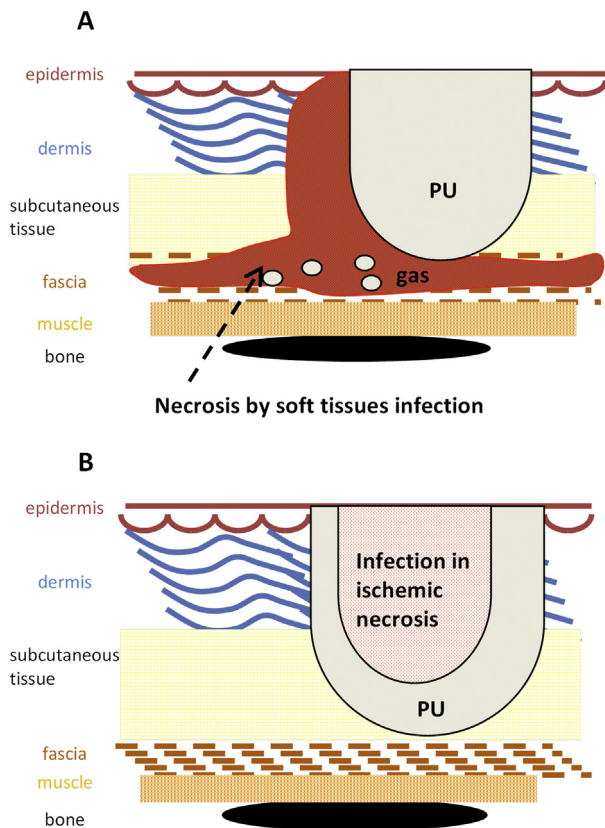


Figure 1 Schematic presentation of the criteria for diagnosing infected pressure ulcers and necrotizing soft tissue infections that developed from a pressure ulcer A, Necrotizing soft tissue infection developed from a pressure ulcer. The tissue necrosis extends beyond the primary lesion caused by the pressure over a bony prominence. PU, pressure ulcer B, Infected pressure ulcer, the tissue necrosis is primarily limited to the ischemic lesion caused by the pressure.

The mean LRINEC score upon admission was 5.5 (range, 2–11), with a score of >5 being observed in 11 cases (Table 1). In all cases, elevated inflammatory markers were observed; serum albumin levels were also generally well maintained at the first observation (data not shown). Among the 24 necrotizing STI patients, 18 (75%) had comorbid dementia and 14 (58%) had comorbid diabetes mellitus.

Characterization of the necrotizing STIs that developed from pressure ulcers

The primary pressure ulcers were mostly located in the buttocks region, including over the sacrum, greater trochanter, coccyx, and ischium (Table 1). Only 1 case of necrotizing STI that developed from a foot pressure ulcer was found in the database. For the diagnoses, computed tomography scans

Table 1 Characteristics of the patients and wounds.

Variable	Value
Age (years); mean and range	82.9 ± 9.2 (65–98)
Gender (male/female); n	10/14
Comorbidities; n (%)	
Dementia	18 (75%)
Diabetes mellitus	14 (58%)
Site of occurrence; n (%)	
Sacrum	11 (46%)
Greater trochanter	4 (17%)
Coccyx	4 (17%)
Ischium	2 (8%)
Foot	1 (4%)
Ilium	1 (4%)
Shoulder	1 (4%)
LRINEC score (mean and range)	5.5 ± 3.3 (2–11)
0–5; n (%)	13 (54%)
6–7; n (%)	3 (13%)
8–13; n (%)	8 (33%)

LRINEC, laboratory risk indicator for necrotizing fasciitis.

were obtained in 21 cases (88%). Complicated pneumonia and urinary tract infection were differentiated upon diagnosis of necrotizing STIs. All of the primary pressure ulcers were stage IV, according to the NPUAP criteria. None of the pressure ulcers showed dominant granulation tissue at the time the necrotizing STI was diagnosed (Fig. 2(A) and (C)). In representative cases (Fig. 2(A)–(D)), surgical debridement exposed the fascia and muscle that appeared to be necrotic, with a gray-blackish appearance (Fig. 2(B) and (D)). In contrast, infected pressure ulcers without necrotizing STIs (Fig. 2(E)) only exhibit yellowish debris, usually called slough, after debridement (Fig. 2(F)).

Bacteria isolated from deep necrotic tissue

Most of the wounds in our database were surgically explored; samples for bacteriology were obtained from the deep tissues, not from the wound surface. All surgical debridements were performed within 72 h of admission. Bacterial cultures, including those for anaerobic bacteria, revealed the presence of multiple organisms in the samples. The most frequently detected pathogen was *Bacteroides fragilis*. A single species of bacteria was recovered from only 1 wound (4%); 2 bacterial species were isolated from 3 (13%) wounds; and ≥3 species were isolated from 20 (83%) wounds. *Corynebacterium* spp., *Staphylococcus aureus* (including methicillin-resistant *S. aureus*; MRSA),

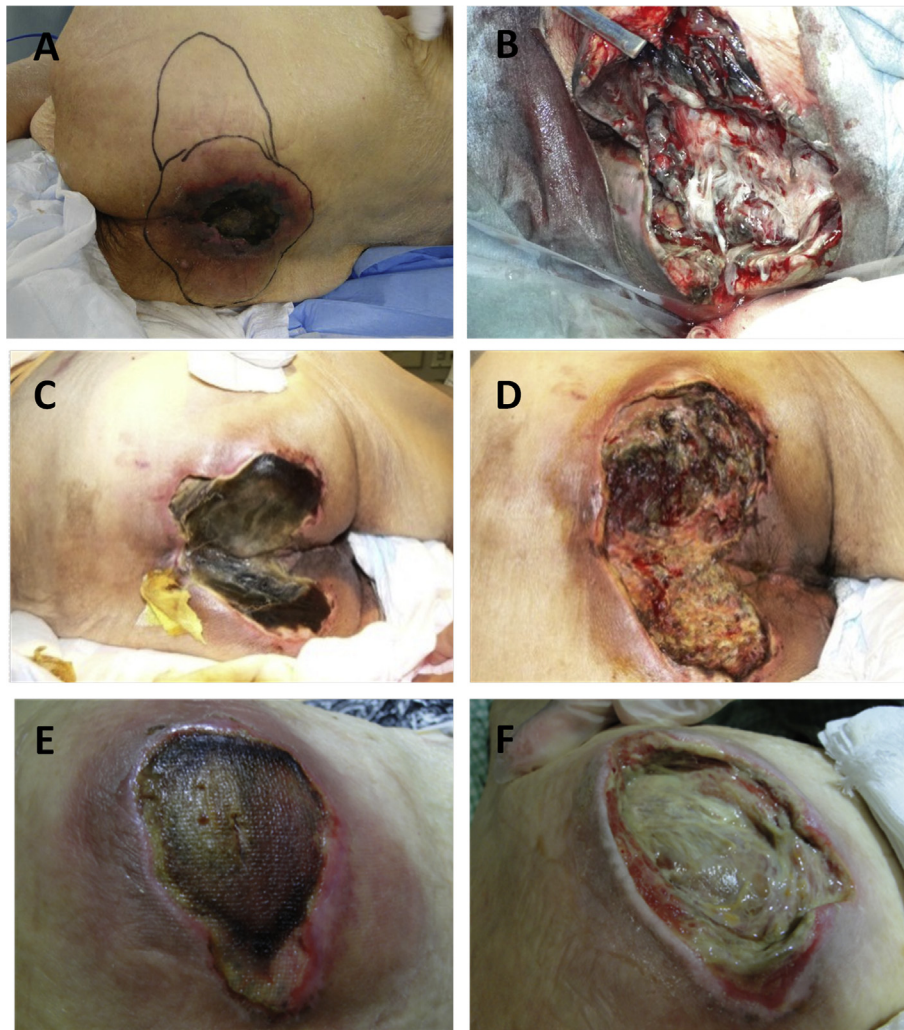


Figure 2 Representative cases of necrotizing soft tissue infections that developed from pressure ulcers and infected pressure ulcers. (A) Necrotizing soft tissue infection developed from pressure ulcer in a 98-year-old woman. The bacteria isolated from the deep tissues were *Proteus vulgaris* and *Enterococcus faecalis*. The palpable lesion, containing gas, is marked. (B) After surgical debridement: the necrosis had reached the fascia. The deep tissue exhibits a gray appearance due to coagulation of blood. (C) Necrotizing soft tissue infection showing a phenotype like gas gangrene from a sacral pressure ulcer occurred in a 71-year-old woman. The bacteria isolated from the deep tissue were *Bacteroides fragilis*. (D) The wound is shown after surgical debridement. (E) An infected pressure ulcer in a 92-year-old woman. (F) After debridement, the deep tissue shows only yellowish appearance, unlike necrotic fasciitis.

and *Peptostreptococcus* spp. were among the gram-positive pathogens that were isolated. Among the gram-negative pathogens, *Enterococcus faecalis*, *Escherichia coli*, and *B. fragilis* were frequently isolated (Table 2). Anaerobic pathogens were isolated from 18 wounds (75%), and 17 wounds (71%) had both aerobic and anaerobic pathogens.

Treatment and outcomes

Of the patients in the database who were diagnosed with necrotizing STIs that had developed from pressure ulcers, all were treated with a

combination of antibiotics and debridement, except for 1 patient whose family refused any surgical treatment. Seven patients (29%) developed bacteremia, with *B. fragilis* being the most frequently isolated pathogen from blood cultures. Antibiotics were administered to all patients, and the type(s) of antibiotic(s) that each patient received is/are shown in Table 3. Appropriate treatment for dehydration was required in all cases. The 30-day mortality rate was 8% (2 patients), despite the advanced age of the patients and their associated comorbidities. The 2 patients who died succumbed to multiple organ failure due to sepsis.

Table 2 Bacterial pathogens isolated from necrotizing soft tissue infections that developed from pressure ulcers.

Pathogen	Value n (%)
Aerobic pathogens	
<i>Corynebacterium</i> sp.	9 (38%)
<i>Enterococcus faecalis</i>	9 (38%)
Methicillin-resistant	8 (33%)
<i>Staphylococcus aureus</i>	
<i>Staphylococcus aureus</i>	7 (29%)
<i>Escherichia coli</i>	6 (25%)
<i>Streptococcus agalactiae</i> (group B)	5 (21%)
<i>Staphylococcus epidermidis</i>	3 (13%)
<i>Proteus vulgaris</i>	3 (13%)
<i>Streptococcus</i> spp. group G	2 (8%)
<i>Klebsiella pneumoniae</i>	2 (8%)
<i>Streptococcus pyogenes</i> (Group A)	1 (4%)
<i>Citrobacter freundii</i>	1 (4%)
<i>Pseudomonas aeruginosa</i>	1 (4%)
<i>Enterobacter cloacae</i>	1 (4%)
Anaerobic pathogens	
<i>Bacteroides fragilis</i>	13 (54%)
<i>Peptostreptococcus</i> sp.	10 (42%)
<i>Clostridium</i> sp.	2 (8%)
<i>Fusobacterium</i> sp.	1 (4%)
<i>Porphyromonas asaccharolytica</i>	1 (4%)
<i>Prevotella bivia</i>	1 (4%)
<i>Propionibacterium acnes</i>	1 (4%)
Simultaneous detection of aerobic and anaerobic pathogens	17 (71%)

Discussion

In this study, a retrospective analysis was conducted to examine necrotizing STIs that arose as complications of pressure ulcers in elderly patients. Because both deep pressure ulcers and necrotizing STIs cause soft tissue necrosis, we

Table 3 Treatment and clinical outcomes of patients with necrotizing soft tissue infections arising from pressure ulcers.

Treatment and outcomes	Patients n (%)
Antibiotic monotherapy	
Carbapenem	13 (54%)
Cephem	6 (25%)
Clindamycin	1 (4%)
Antibiotic combination therapy	
Carbapenem + clindamycin	4 (17%)
Surgical debridement	23 (96%)
Bacteremia	7 (29%)
30-day mortality	2 (8%)

defined necrotizing STIs developing from pressure ulcers (Fig. 1). By this definition, patients with cellulitis and infections limited to the necrotic tissue of the pressure ulcer were excluded.

Dementia was frequently observed among the patient population because of the advanced age of the patients included in this study. The dementia likely complicated and delayed the determination of infection; therefore, pressure ulcer patients with co-morbid dementia may be at a higher risk for the development of severe STIs. Previously reported studies have not focused on the relationship between dementia and infected pressure ulcers; however, our observation highlights the importance of comorbid dementia. Severe infections are worse in patients with diabetes [6], and diabetes was also frequently observed in the patients in the present study.

Necrotizing STI, also called gangrenous cellulitis, has been classified in various manners. Rapidly progressive NFs are caused by group A *Streptococcus* and are classified as type II NF. However, necrotizing STIs from pressure ulcers are likely distinct entities. Indeed, the average LRINEC score in this study was lower than that reported in other NF studies [7]. Although renal clearance is reduced in the elderly, serum creatinine levels tend to decrease because of muscle loss [8,9]. Furthermore, local atrophy of muscle over a bony prominence is a major risk factor for the development of the primary pressure ulcer. Therefore, the mass of damaged muscle is relatively small in patients with pressure ulcers. Hence, serum creatinine level may be an inappropriate marker for evaluating necrotizing STIs in elderly patients with pressure ulcers. Similarly, inflammatory responses, including white blood cell counts and CRP levels, may be lower in elderly patients with pressure ulcers.

An advantage of this study was that bacteriology samples were obtained from deep necrotic tissues, such as subcutaneous fat tissue, fascia, ligaments, and tendons. Previous studies [7,10] have not mentioned the method used for obtaining bacteriology samples; therefore, the current study is informative regarding the types of bacterial colonization existing in these types of necrotizing STIs. Although streptococcal NF is characterized as a fulminant infection, none of the cases of necrotizing STIs in this study were diagnosed as streptococcal NF. Indeed, *Enterococcus* spp. as well as anaerobic pathogens, including *B. fragilis* and *Peptostreptococcus* spp., were frequently isolated from the wounds in this study.

In this study, the presence of necrotic tissue, not granulation tissue was an initiation factor for necrotizing STIs that developed as an extension of

a pressure ulcer. Moreover, the anatomic location of a pressure ulcer may be a critical factor in the development of necrotizing STIs because the opportunity for fecal infection is higher for sacral and coccygeal pressure ulcers [11]. The necrotizing STIs developed from pressure ulcers demonstrated mainly polymicrobial infections, with both aerobic and anaerobic pathogens frequently observed in the chronic wounds [12,13].

Although the cases reported in present study involved elderly patients with multiple comorbidities, the mortality rate was lower than that reported previously [14]. One of the reasons for the lower mortality rate was that surgical intervention (debridement) was performed in 23 of the 24 cases at the initial stage. Another reason might be the appropriate use of broad-spectrum antibiotics to treat the multiple pathogens associated with these infections.

This study was conducted in a limited number of patients; however, it provides information regarding the characteristics of these necrotizing STIs that develop from pressure ulcers. This important complication needs to be recognized in order to achieve effective management of pressure ulcers.

Conflict of interest

The authors declare that they have no conflicts of interest.

Acknowledgments

Funding for this study was provided by Research Funding for Longevity Sciences (23-13) (to ZI and KF) from the National Center for Geriatrics and Gerontology (NCGG), Japan. We thank Yoshiko Takahashi for editorial assistance.

References

- [1] Elliott DC, Kufera JA, Myers RA. Necrotizing soft tissue infections. Risk factors for mortality and strategies for management. *Ann Surg* 1996;224:672–83.
- [2] McHenry CR, Piotrowski JJ, Petrinic D, Malangoni MA. Determinants of mortality for necrotizing soft-tissue infections. *Ann Surg* 1995;221:558–63.
- [3] Livesley NJ, Chow AW. Infected pressure ulcers in elderly individuals. *Clin Infect Dis* 2002;35:1390–6.
- [4] Smith PW, Black JM, Black SB. Infected pressure ulcers in the long-term-care facility. *Infect Control Hosp Epidemiol* 1999;20:358–61.
- [5] Wong CH, Khin LW, Heng KS, Tan KC, Low CO. The LRINEC (Laboratory Risk Indicator for Necrotizing Fasciitis) score: a tool for distinguishing necrotizing fasciitis from other soft tissue infections. *Crit Care Med* 2004;32:1535–41.
- [6] Lipsky BA, Berendt AR, Cornia PB, et al. 2012 Infectious Diseases Society of America clinical practice guideline for the diagnosis and treatment of diabetic foot infections. *Clin Infect Dis* 2012;54.
- [7] Citak M, Backhaus M, Tilkorn DJ, et al. Necrotizing fasciitis in patients with spinal cord injury: an analysis of 25 patients. *Spine* 2011;36:E1225–9.
- [8] Hanlon JT, Schmader KE, Koronkowski MJ, et al. Adverse drug events in high risk older outpatients. *J Am Geriatr Soc* 1997;45:945–8.
- [9] Liu GG, Christensen DB. The continuing challenge of inappropriate prescribing in the elderly: an update of the evidence. *J Am Pharm Assoc* 2002;42:847–57.
- [10] Backhaus M, Citak M, Tilkorn DJ, Meindl R, Schildhauer TA, Fehmer T. Pressure sores significantly increase the risk of developing a Fournier's gangrene in patients with spinal cord injury. *Spinal Cord* 2011;49:1143–6.
- [11] Cantrell M, Norman DC. Skin and soft-tissue infections in the elderly. In: Bula CJ, Kauffman CA, editors. *Bailliere's clinical infectious diseases*, vol. 5. London: Bailliere Tindall; 1998. pp. 71–81.
- [12] Bowler PG. Wound pathophysiology, infection and therapeutic options. *Ann Med* 2002;34:419–27.
- [13] Drinka P, Bonham P, Crnich CJ. Swab culture of purulent skin infection to detect infection or colonization with antibiotic-resistant bacteria. *J Am Med Dir Assoc* 2012;13:75–9.
- [14] Citak M, Fehmer T, Backhaus M, et al. Does spinal cord injury influence the mortality rate in patients with necrotizing fasciitis? *Spinal Cord* 2012;50:338–40.